ALPINION
MEDICAL SYSTEMS

ALPINION MEDICAL SYSTEMS
Verdi Tower, 72, Digital-ro (St) 26-gil (Rd), Guro-gu, Seoul, 08393, Republic of Korea
Homepage : www.alpinion.com
E-mail : inernational@alpinion.com
Tel : 82-2-3282-0900
Fax : 82-2-851-5591

Standalone clinical images may have been cropped to better visualize pathology.

MKT-E15-CL-E1603-01

ECUBE 15 EX

Clinical Values

E-CUBE 15 EX Elastography

Qualitative and Semi-Quantitative Elastography

Ultrasound elastography is a non-invasive diagnostic technique performed in combination with conventional B-mode ultrasound to help assess tissue stiffness. Strain elastography can help clinicians characterize abnormal tissue by assessing the stiffness in relationship to surrounding tissue. The field of medicine in breast, thyroid, musculoskeletal area and even gynecology widely accepts the principle that most malignant lesions have a harder or stiffer consistency than surrounding benign tissue.

ALPINION 's Elastography is an emerging technology in ultrasound diagnosis for the assessment and real-time color display of tissue elasticity.

Enhanced E-CUBE 15 EX adopts simple compression, displacing the underlying anatomical structures. Proprietary software estimates the strain on tissue in a region of interest and creates an elastogram, displayed as a real-time color map of relative elasticity, superimposed on the B-mode.

E-CUBE 15 EX qualitative and semi-quantitative packages provide useful clinical information and improved diagnostic confidence.

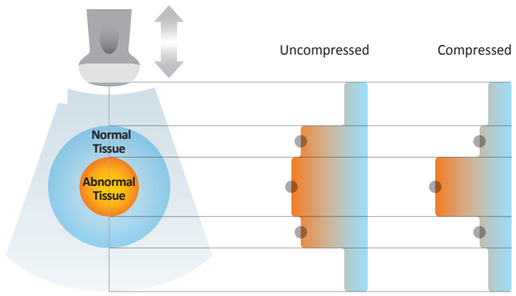

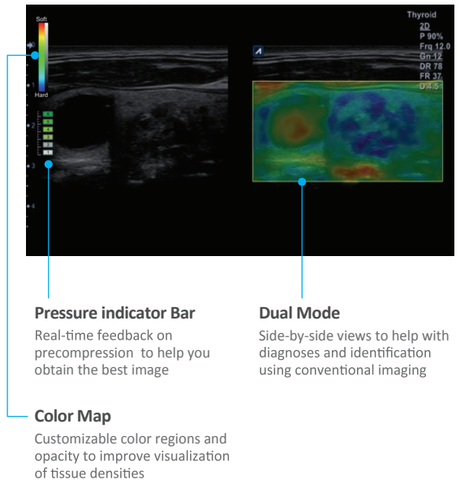

Key Benefits

Highly Sensitive — Real-time elasticity imaging through improved tissue motion tracking and data acquisition techniques

Highly Accurate — Displays extracting strain data using measurements via a Strain Ratio tool and a pressure quality indicator

Highly Intuitive — Helps streamline workflow by performing fast, accurate, reproducible results with intuitive user-interface

Case Study

Clinical usefulness of Elastography for rehabilitation of athletes with muscle injury

Introduction

Ultrasound (US) sonography has been well-known for its usefulness in assessing musculoskeletal pathology, and recent studies have revealed that the combination of US elastography may be a useful tool for the evaluation of musculoskeletal disorders and even for monitoring the effect of rehabilitation therapy. The purpose of this case study was to evaluate the clinical usefulness of US elastography in the diagnosis and treatment of athletes with rectus femoris tears.

Case 1

For this study, B-mode US and sonoelastography were performed using the E-CUBE 15 EX (ALPINION MEDICAL SYSTEMS, South Korea) with a 3-12 MHz linear probe.

A 14-year old female patient, a sprinter, was presented to the clinic with complaints of anterior thigh pain beginning three weeks before presentation. Conventional US and the combination US elastography were performed and it was clearly shown in the elastography imaging that a muscle tear was partially observed and its size was about 4.5 cm long by 1.3 cm wide by 1.0 cm deep, in the deep rectus femoris. Physical therapy and injections were used for pain management and for healing the injured muscle, along with ultrasound sonography combined with US elastography, every two weeks. In the 4th week after the initial evaluation – the 7th week following the injury onset – MSK US was used to document the status after intervention. The US images showed that the involved muscle tissue had healed, but elasticity was reduced during US elastogram. Her return to training was delayed and her condition was monitored for 1-2 weeks during follow-up visits. In the 6th week following the initial evaluation – the 9th week following the injury onset – as a result of the follow-up, the elastography indicated that there was a recovery of elasticity. She was able to return to athletics without reoccurrence of any symptoms. After the 3rd month following the initial evaluation – the 4th month following the injury onset - the fibrotic muscle was reduced. There were no abnormal findings but it was confirmed that elasticity in the repaired muscle was partially reduced in the US elastography.

Conclusion

In terms of diagnosis and treatment of muscle injuries, it has been confirmed that real-time strain elastography can be utilized as an easier serial follow up tool for improvement of understanding such injuries and their healing process, as it is efficient in cost and time.

Elastography can provide an accurate diagnosis of musculoskeletal injuries and may help prevent athletes from injuring themselves further during rehabilitation sessions, which can be a useful tool for evaluating when an athlete can return to training.

Clinical Image

Real-time Strain Elastography in Muscle Injury

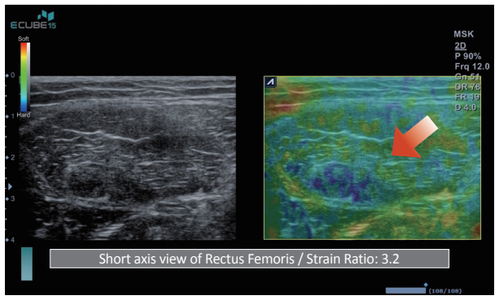

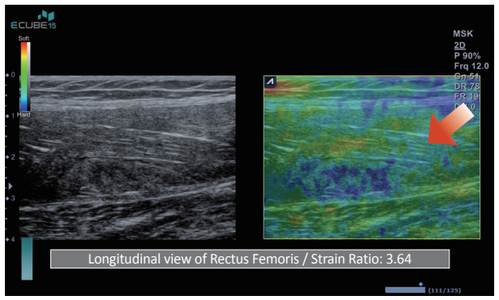

Initial visit

Partial rupture in rectus femoris is more clearly identified with elastography mode than 2D mode, with the SR values of 3.2-3.64 measured from the site. (Blue color mapping: Hard lesion)

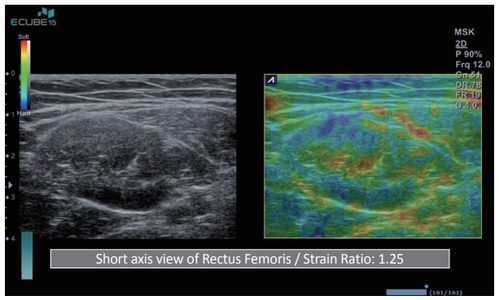

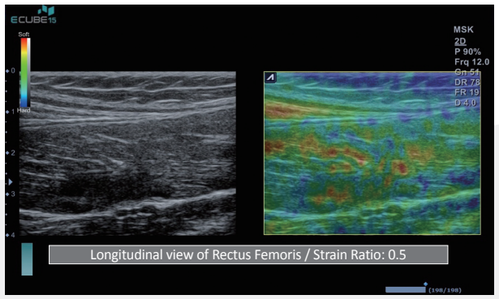

Follow-up: 3 months Later

There was nothing more than partially reduced elasticity, as the SR values of 0.5-1.25 measured from the site

Excerpted from The Korean Journal of Sports Medicine
Images by courtesy of SH Choi, MD
Yonsei SOL Sports and Orthopedics Rehabilitation Center, South Korea,
Supported system: E-CUBE 15 V.3.0

Case Study

Semi-quantitative and Qualitative Assessment of Breast Ultrasound Elastography in differentiating between Malignant and Benign Lesions

171 breast lesions were evaluated by B-mode and elastography imaging using E-CUBE 15 EX in a tertiary medical center, South Korea from July to December, 2015.

Introduction

In recent years, the interpretation of breast nodules detected via ultrasound has depended mainly on morphological criteria. To improve the accuracy of USG, additional techniques can be used, including Doppler and harmonic imaging. The lesion's contours, dimensions, color, strain ratio, and appearance in elastography are some of the criteria used for differentiating benign from malignant lesions. The strain ratio shows the relative stiffness of lesions compared to surrounding tissue. Malignant lesions are usually very stiff, with less deformation, and are displayed in blue on the elastography images, whereas benign lesions deform much more easily and are depicted in red.

In this clinical evaluation study, we evaluated 171 breast lesions by B-mode and elastogram using E-CUBE 15 EX. Elastography by E-CUBE 15 EX is easy to perform and shows direct visual information by color and strain ratio. SR helped us distinguish BI-RAD III-IV lesions with direct visual information. Elastography shows the relative softness, which can prevent unnecessary biopsy. In the near future, elastograms might be added to all ultra sonogram devices and be included in diagnostic criteria.

Conclusion

Performing breast elastography on the E-CUBE 15 EX is a simple, fast method to improve breast diagnostics using USG. USG combined with SE is the most non-invasive and accessible imaging method, with the lowest cost/efficiency ratio, for decreasing unnecessary biopsies. Elastography, in combination with B-mode imaging using the E-CUBE 15 EX, provides additional information to help physicians make clinical decisions with diagnostic confidence.

Supported System: E-CUBE 15 EX V.3.1

Clinical Image

Fibroadenoma (Benign)

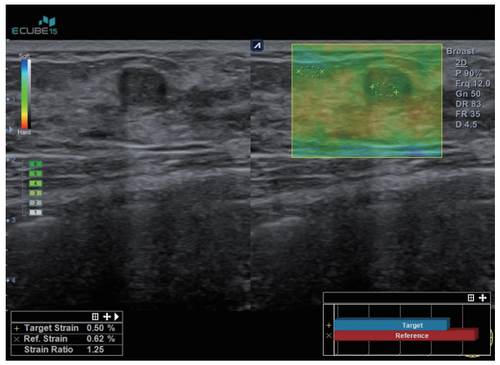

The lesion measured 0.9 cm in size, with an oval shaped and smooth margins, classified BI-RAD III. An elastogram revealed the stiffness of the lesion, indicated by yellow-blue, in contrast to the fat tissue, indicated by yellow-red. The strain ratio was 1.25. Biopsy result was fibroadenoma.

Invasive Ductal Carcinoma (Malignant)

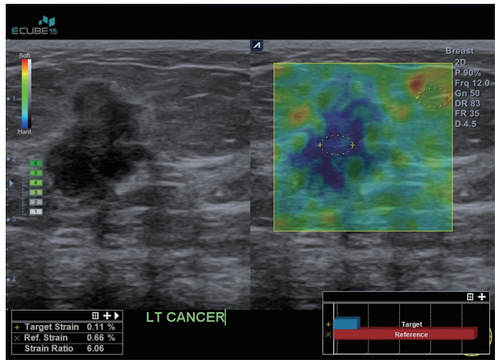

The lesion was 1.67cm in size, irregularly shaped, hypoechoic with indistinct margins, classified BI-RAD IV c. Elastogram revealed stiffness, indicated in blue, while the fat tissue was red. The strain ratio was 6.06. Biopsy result was invasive ductal carcinoma.

Elastogram and B-mode scan by E-CUBE 15 EX showed a very accurate image and provided information to help physicians make decisions.

Ductal Carcinoma in situ (Malignant)

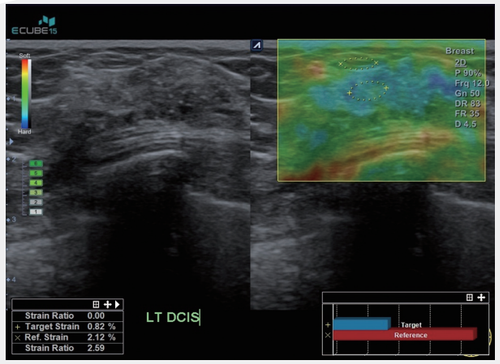

The lesion was 2.56cm, a hypoechoic mass with internal calcification, irregularly shaped indistinct margins and posterior acoustic shadow, classified BI-RAD IV b. Elastogram revealed stiffness, indicated by blue, contrasted with yellow fat tissue and a Strain ratio of 2.59. Biopsy result was ductal carcinoma in situ.